



Owner's Copy

PennHIP Report

Referring Veterinarian: Dr Brian Keller	Clinic Name: Countryside Veterinary Clinic (WI)
Email: countrysidevet@frontiernet.net	Clinic Address: 1231 N Knowles Ave New Richmond, WI 54017
	Phone: (715) 246-5606
	Fax: (715) 246-9256

Patient Information

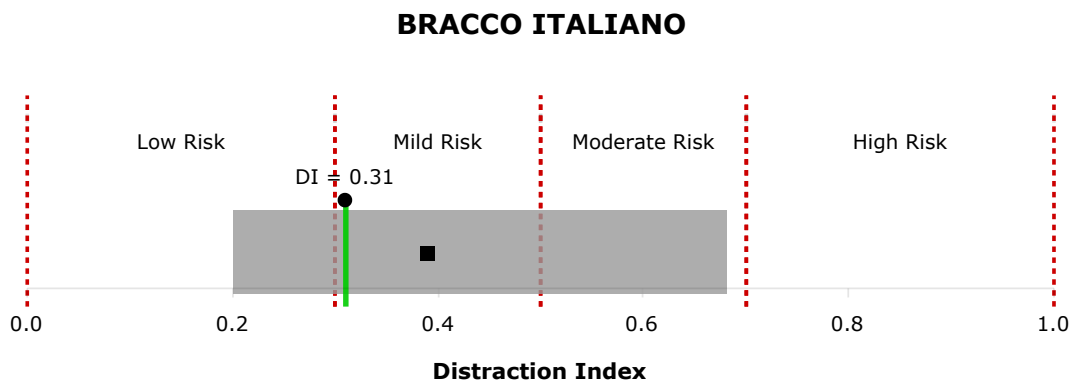
Client: Freese, Jesse	Tattoo Num: None
Patient Name: Albi	Patient ID: 17359Albi
Reg. Name: Noblenose Albizzo	Registration Num: BI-000423
PennHIP Num: 147004	Microchip Num: None
Species: Canine	Breed: BRACCO ITALIANO
Date of Birth: 14 May 2018	Age: 28 months
Sex: Male	Weight: 66 lbs/29.9 kgs
Date of Study: 16 Sep 2020	Date Submitted: 21 Sep 2020
Date of Report: 21 Sep 2020	

Findings

Distraction Index (DI): Right DI = 0.31, Left DI = 0.29.
 Osteoarthritis (OA): **No radiographic evidence of OA for either hip.**
 Cavitation/Other Findings: No cavitation present.

Interpretation

Distraction Index (DI): The laxity ranking is based on the hip with the greater laxity (larger DI). In this case the DI used is 0.31.
 OA Risk Category: The DI is between 0.31 and 0.49. This patient is at mild risk for hip OA.
 Distraction Index Chart:



BREED STATISTICS: This interpretation is based on a cross-section of 122 canine patients of the BRACCO ITALIANO breed in the AIS PennHIP database. The gray strip represents the central 90% range of DIs (0.20 - 0.68) for the breed. The breed average DI is 0.39 (solid square). The patient DI is the solid circle (0.31).

SUMMARY: The degree of laxity (DI = 0.31) falls within the central 90% range of DIs for the breed. This amount of hip laxity places the hip at a mild risk to develop hip OA. **No radiographic evidence of OA for either hip.**